

An adhesive ocular bandage for the conjunctival-limbal wound in fornix-based trabeculectomy surgery

Mr Dan Calladine, Mr Gokulan Ratnarajan and Mr James McAllister
Prince Charles Eye Unit, Windsor, UK

Introduction

In fornix-based trabeculectomy surgery the conjunctival-limbal incision is typically closed using 10/0 nylon sutures. A variety of suturing techniques exist, which range from the simplest being 2 interrupted sutures placed at each end of the conjunctival relieving incision to more complicated mattress type sutures. Several authors now advocate the use of 'purse string' sutures to help guarantee closure of this wound as part of a 'safe surgery' technique.¹

However, despite paying careful attention to the closure of this wound and even in the hands of an experienced glaucoma surgeon, leakage can occur from the conjunctival-limbal wound in the immediate post operative period. This can lead to complications such as hypotony, a shallow anterior chamber, a flat trabeculectomy bleb, choroidal detachments, infection and loss of vision and may require surgical repair. Leakage from this wound has become more common with the increasing use of anti-metabolites such as mitomycin-C (MMC) to modify wound healing and an ageing surgical population who tend to have thin and fragile conjunctiva.²⁻⁵

The authors present a new technique where the ReSure™ Adherent Ocular Bandage is used in combination with 2 simple sutures to seal the conjunctival-limbal incision following trabeculectomy surgery. Eight cases of trabeculectomy surgery covering a variety of patient demographics and surgical techniques with and without anti-metabolites are presented. Patients were examined using the slight lamp, 2% fluorescein Seidel test and intraocular pressure (IOP) measurement at 1 hour, 1 day and 7 days following surgery. Colour slit lamp photography was used to document coverage of the bandage material.

Methods

Prospective consecutive study was conducted of 8 patients undergoing trabeculectomy surgery by the same surgeon (JMA) at the Prince Charles Eye Unit, Windsor, UK.

In all cases the conjunctival relieving incision was closed using a simple technique of 2 interrupted 10/0 nylon conjunctival/corneal sutures with buried knots, one placed at each end. The wound was then dried thoroughly using a sponge and the ReSure Adherent Ocular Bandage (Ocular Therapeutix Inc., Boston, USA) was applied over the conjunctival-limbal wound.

All eyes were examined in the immediate postoperative period, and again at 1-day and 7-days following surgery. At each time point, coverage of the bandage material was documented using colour slit lamp photography, intraocular pressure was measured and a Seidel test performed.

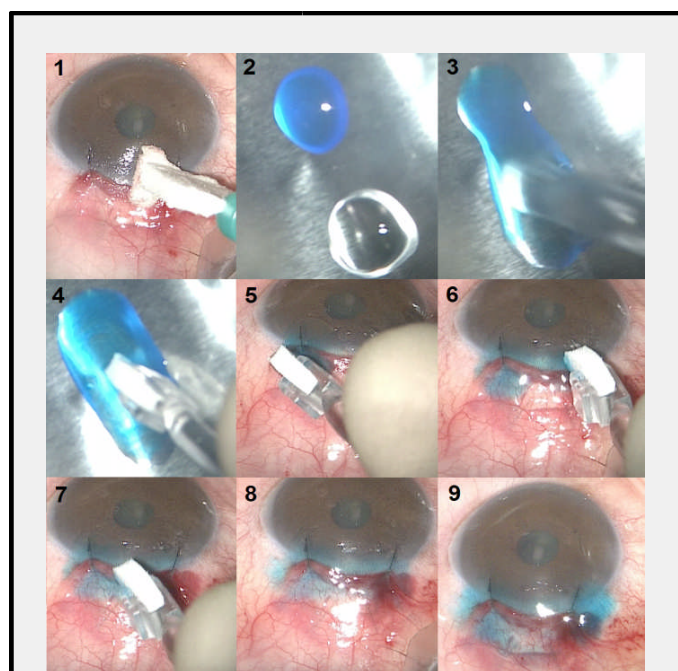


Figure 1: Sequential images taken down the operative microscope showing application of the bandage. 1 the wound is dried; 2-4 the 2 components of the bandage material are mixed to activate the polymerisation process; 5-6 the first transfer of bandage material is sufficient to cover each relieving incision; 7 a second transfer of material from the same mixture is applied to the middle of the wound; 8 the incision and sutures are completely covered with bandage material and left to dry for 30 seconds; 9 a third transfer of bandage material has been applied to the relieving incision on the right hand side to finish the operation.

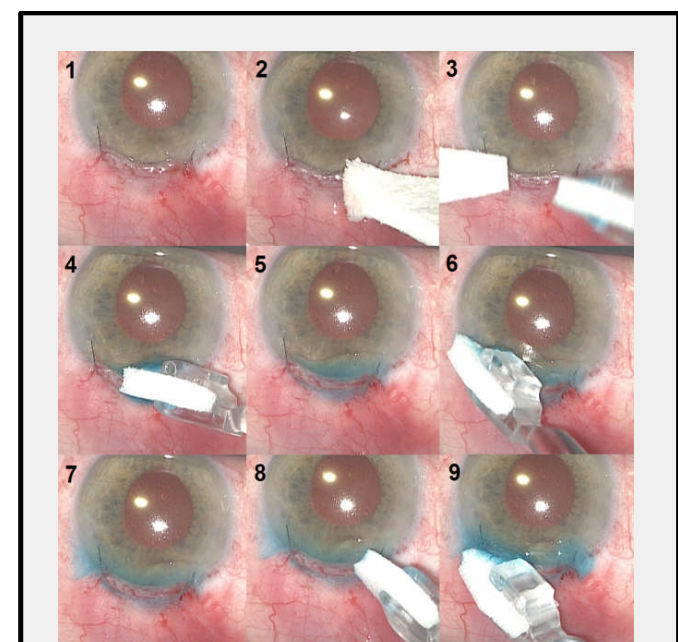


Figure 2: Sequential images taken down the operative microscope showing application of the bandage. 1 the appearance at the end of surgery; 2-5 the wound is dried using a sponge held in the surgeon's left hand and immediately afterwards the first transfer of bandage material is applied using the applicator foam tip held in the surgeon's right hand; 6 second transfer of material from the same mixture is applied to the other end of the wound; 7-9 a third transfer of bandage material is applied to cover each relieving incision to finish the operation.

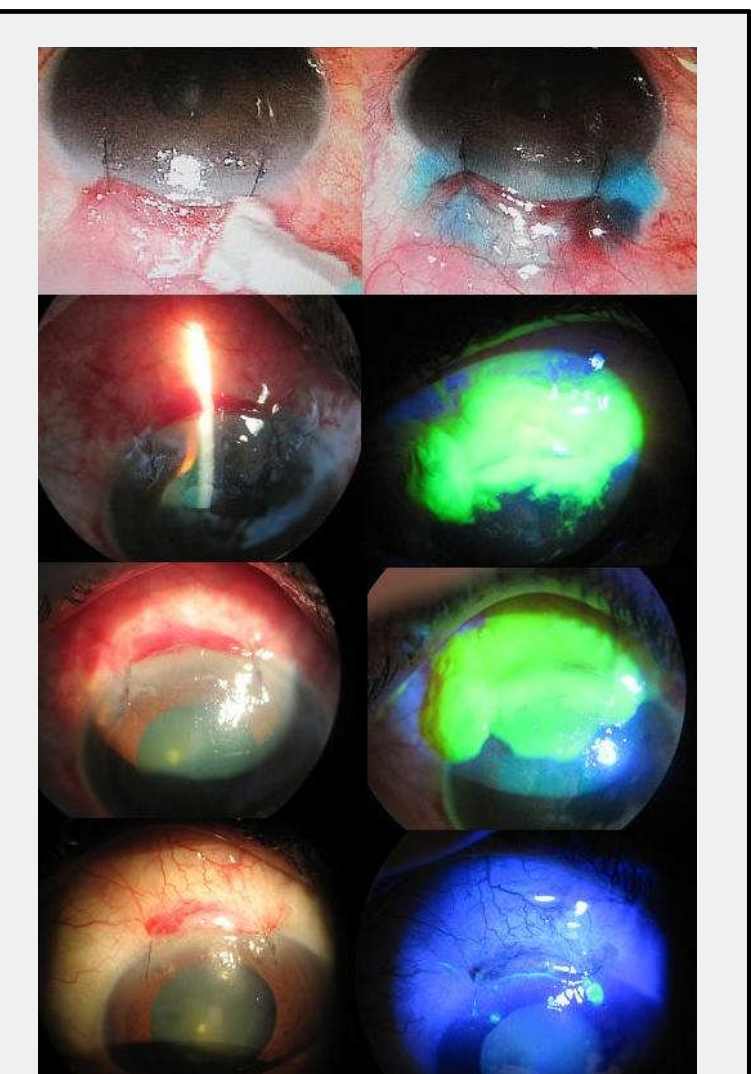


Figure 3: Sequential photographs of the adherent ocular bandage. During surgery the conjunctival-limbal wound is dried (top left) and the bandage material applied (top right). In the immediate postoperative period (2nd down) the bandage material can be seen stained with fluorescein and is slightly raised and irregular. At the day-1 examination (2nd up) the bandage material has adopted a smooth surface profile and the bleb can be seen formed just behind the posterior edge of the bandage. At the day-7 examination only a few remnants of the bandage material remain adhered around the sutures (bottom).

Results

Full coverage of the conjunctival-limbal wound was seen in all 8 cases at 1 hour. Full coverage of the wound was seen in 75% of eyes at day-1.

Gradual replacement of the bandage material was seen over the week following surgery. By day-7, 2 cases still had a partial coverage of bandage material but this was localised to the area around the sutures and absent from the middle of the wound (figure 1). In both these cases the sutures were removed at this time, which also removed the last remnants of the bandage material. In the remaining 6 cases all the bandage material had gone.

None of the wounds were found to be leaking and all had a visible posteriorly placed bleb. In all cases patients experienced no discomfort following their surgery and no complications were seen from the use of the adherent ocular bandage in this way.

Patient	Age	Diagnosis	Surgery	Bandage cover and IOP (mmHg)			Bleb characteristics and Seidel test		
				1-hour	1-day	7-days	1-hour	1-day	7-days
1	60	POAG	Trab + MMC	Full (20)	Full (15)	Partial (15)	Flat (-)	Raised (-)	Raised (-)
2	70	POAG	Trab	Full (15)	Full (14)	Partial (15)	Raised (-)	Raised (-)	Raised (-)
3	75	POAG	Phaco-trab	Full (12)	Partial (8)	None (8)	Flat (-)	Raised (-)	Raised (-)
4	70	POAG	Trab re-do+MMC	Full (14)	Partial (8)	None (14)	Raised (-)	Raised (-)	Raised (-)
5	80	POAG	Trab	Full (8)	Partial (9)	None (4)	Raised (-)	Raised (-)	Raised (-)
6	82	POAG	Trab	Full (10)	Partial (15)	None (14)	Raised (-)	Raised (-)	Raised (-)
7	66	POAG	Trab + MMC	Full (15)	Partial (23)	None (21)	Flat (-)	Raised (-)	Raised (-)
8	85	POAG	Trab	Full (15)	Partial (23)	None (21)	Flat (-)	Raised (-)	Raised (-)

Table 1: The 8 cases in the study showing the patient demographics, the type of surgery, the bandage cover, IOP, bleb characteristics and Seidel test.

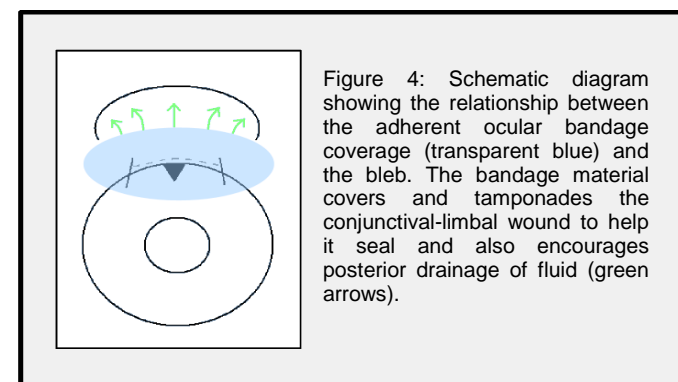


Figure 4: Schematic diagram showing the relationship between the adherent ocular bandage coverage (transparent blue) and the bleb. The bandage material covers and tamponades the conjunctival-limbal wound to help it seal and also encourages posterior drainage of fluid (green arrows).

Conclusions

This adherent ocular bandage forms smooth, comfortable protective covering over the limbal-conjunctival wound.

This study demonstrated how it can be used with a relatively simple suturing technique to help seal the wound.

The application of the bandage material is quick and easy, short learning curve, giving 100% coverage in all cases. For this reason represents a viable alternative to more complicated suturing techniques (mattress sutures/ purse-string sutures).

The authors suggest the bandage material will be particularly helpful in elderly patients with thin fragile conjunctiva and with increasing use of antimetabolites to modify wound healing.

The bandage material also helped to tamponade the anterior aspect of the scleral flap and encouraged posterior drainage and bleb formation.

References

- Jones E, Clarke J, Khaw PT. Recent advances in trabeculectomy technique. *Curr Opin Ophthalmol*. 2005 Apr;16(2):107-13.
 Radhakrishnan S, Quigley HA, Jampel HD, et al. Outcomes of surgical bleb revision for complications of trabeculectomy. *Ophthalmology*. 2009 Sep;116(9):1713-8. Epub 2009 Jul 29
 Song A, Scott IU, Flynn HW Jr, et al. Delayed-onset bleb-associated endophthalmitis: clinical features and visual acuity outcomes. *Ophthalmology*. 2002 May;109(5):985-91.
 Georgoulas S, Dahlmann-Noor A, Brocchini S, et al. Modulation of wound healing during and after glaucoma surgery. *Prog Brain Res*. 2008;173:237-54.
 Tannenbaum DP, Hoffman D, Greaney MJ, et al. Outcomes of bleb excision and conjunctival advancement for leaking or hypotonous eyes after glaucoma filtering surgery. *Br J Ophthalmol*. 2004 Jan;88(1):99-103.